Table 2 Normal values for 2D echocardiographic parameters of LV size and function according to gender

Parameter	Male		Female	
	Mean ± SD	2-SD range	Mean ± SD	2-SD range
LV internal dimension				
Diastolic dimension (mm)	50.2 ± 4.1	42.0–58.4	45.0 ± 3.6	37.8–52.2
Systolic dimension (mm)	32.4 ± 3.7	25.0–39.8	28.2 ± 3.3	21.6–34.8
LV volumes (biplane)				
LV EDV (mL)	106 ± 22	62–150	76 ± 15	46–106
LV ESV (mL)	41 ± 10	21–61	28 ± 7	14–42
LV volumes normalized by BSA				
LV EDV (mL/m^2)	54 ± 10	34–74	45 ± 8	29–61
LV ESV (mL/m^2)	21 ± 5	11–31	16 ± 4	8–24
LV EF (biplane)	62 ± 5	52–72	64 ± 5	54–74

BSA, body surface area; *EDV*, end-diastolic volume; *EF*, ejection fraction; *ESV*, end-stystolic volume; *LV*, left ventricular; *SD*, standard deviation.

Table 4 Normal ranges and severity partition cutoff values for 2DE-derived LV EF and LA volume

	Male				Female			
	Normal range	Mildly abnormal	Moderately abnormal	Severely abnormal	Normal range	Mildly abnormal	Moderately abnormal	Severely abnormal
LV EF (%)	52–72	41–51	30–40	<30	54–74	41–53	30–40	<30
Maximum LA volume/BSA (mL/m^2)	16–34	35–41	42–48	>48	16–34	35–41	42–48	>48

Table 6 Normal ranges for LV mass indices

	Women	Men
Linear method		
LV mass (g)	67–162	88–224
LV mass/BSA (g/m^2)	***43–95***	***49–115***
Relative wall thickness (cm)	0.22–0.42	0.24–0.42
Septal thickness (cm)	***0.6–0.9***	***0.6–1.0***
Posterior wall thickness (cm)	***0.6–0.9***	***0.6–1.0***
2D method		
LV mass (g)	66–150	96–200
LV mass/BSA (g/m^2)	***44–88***	***50–102***

Bold italic values: recommended and best validated.

Table 10 Normal values for parameters of RV function

Parameter	Mean ± SD	Abnormality threshold
TAPSE (mm)	24 ± 3.5	<17
Pulsed Doppler S wave (cm/sec)	14.1 ± 2.3	<9.5
Color Doppler S wave (cm/sec)	9.7 ± 1.85	<6.0
RV fractional area change (%)	49 ± 7	<35
RV free wall 2D strain* (%)	−29 ± 4.5	>−20 (<20 in magnitude with the negative sign)
RV 3D EF (%)	58 ± 6.5	<45
Pulsed Doppler MPI	0.26 ± 0.085	>0.43
Tissue Doppler MPI	0.38 ± 0.08	>0.54
E wave deceleration time (msec)	180 ± 31	<119 or >242
E/A	1.4 ± 0.3	<0.8 or >2.0
e′/a′	1.18 ± 0.33	<0.52
e′	14.0 ± 3.1	<7.8
E/e′	4.0 ± 1.0	>6.0

MPI, Myocardial performance index.
*Limited data; values may vary depending on vendor and software version.

Table 8 Normal values for RV chamber size

Parameter	Mean ± SD	Normal range
RV basal diameter (mm)	33 ± 4	25-41
RV mid diameter (mm)	27 ± 4	19-35
RV longitudinal diameter (mm)	71 ± 6	59-83
RVOT PLAX diameter (mm)	25 ± 2.5	20-30
RVOT proximal diameter (mm)	28 ± 3.5	21-35
RVOT distal diameter (mm)	22 ± 2.5	17-27
RV wall thickness (mm)	3 ± 1	1-5
RVOT EDA (cm^2)		
Men	17 ± 3.5	10-24
Women	14 ± 3	8-20
RV EDA indexed to BSA (cm^2/m^2)		
Men	8.8 ± 1.9	5-12.6
Women	8.0 ± 1.75	4.5-11.5
RV ESA (cm^2)		
Men	9 ± 3	3-15
Women	7 ± 2	3-11
RV ESA indexed to BSA (cm^2/m^2)		
Men	4.7 ± 1.35	2.0-7.4
Women	4.0 ± 1.2	1.6-6.4
RV EDV indexed to BSA (mL/m^2)		
Men	61 ± 13	35-87
Women	53 ± 10.5	32-74
RV ESV indexed to BSA (mL/m^2)		
Men	27 ± 8.5	10-44
Women	22 ± 7	8-36

EDA, end-diastolic area; *ESA*, end-systolic area; *PLAX*, parasternal long-axis view; *RVOT*, RV outflow tract.

Table 13 Normal RA size obtained from 2D echocardiographic studies

	Women	Men
RA minor axis dimension (cm/m^2)	1.9 ± 0.3	1.9 ± 0.3
RA major axis dimension (cm/m^2)	2.5 ± 0.3	2.4 ± 0.3
2D echocardiographic RA volume (mL/m^2)	21 ± 6	25 ± 7

Data are expressed as mean ± SD.

Table 14 Aortic root dimensions in normal adults

Aortic Root	Absolute values (cm)		Indexed values (cm/m^2)	
	Men	Women	Men	Women
Annulus	2.6 ± 0.3	2.3 ± 0.2	1.3 ± 0.1	1.3 ± 0.1
Sinuses of Valsalva	3.4 ± 0.3	3.0 ± 0.3	1.7 ± 0.2	1.8 ± 0.2
Sinotubular junction	2.9 ± 0.3	2.6 ± 0.3	1.5 ± 0.2	1.5 ± 0.2
Proximal ascending aorta	3.0 ± 0.4	2.7 ± 0.4	1.5 ± 0.2	1.6 ± 0.3

Adapted from Roman *et al.*[195] and Hiratzka *et al.*[204]

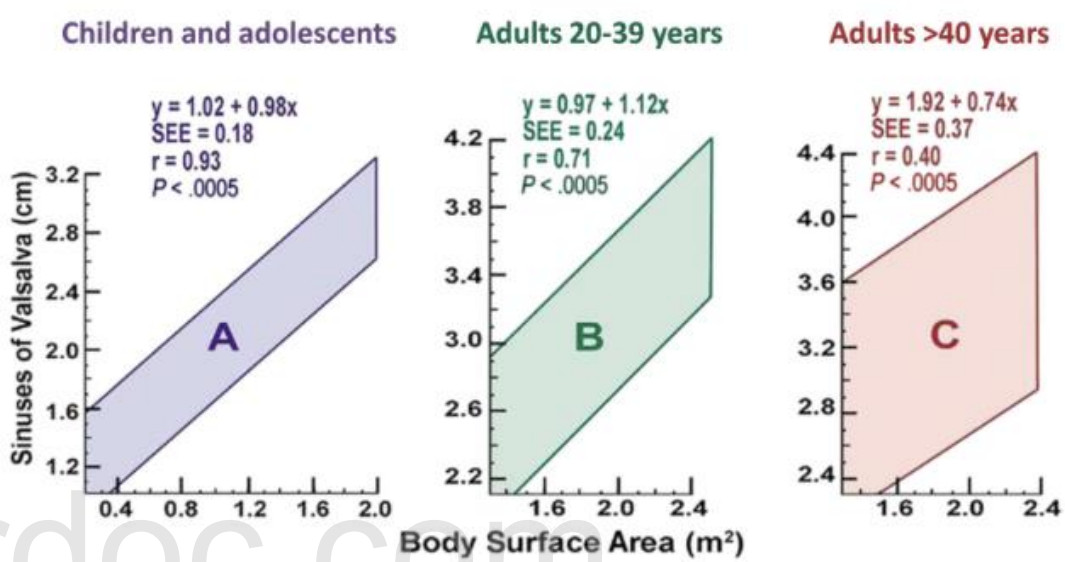

Table 6. Stages of Valvular AS

Stage	Definition	Valve Anatomy	Valve Hemodynamics	Hemodynamic Consequences	Symptoms
A	At risk of AS	• Bicuspid aortic valve (or other congenital valve anomaly) • Aortic valve sclerosis	• Aortic V_{max} <2 m/s	• None	• None
B	Progressive AS	• Mild-to-moderate leaflet calcification of a bicuspid or trileaflet valve with some reduction in systolic motion or • Rheumatic valve changes with commissural fusion	• Mild AS: Aortic V_{max} 2.0–2.9 m/s or mean ΔP <20 mm Hg • Moderate AS: Aortic V_{max} 3.0–3.9 m/s or mean ΔP 20–39 mm Hg	• Early LV diastolic dysfunction may be present • Normal LVEF	• None
C: Asymptomatic severe AS					
C1	Asymptomatic severe AS	• Severe leaflet calcification or congenital stenosis with severely reduced leaflet opening	• Aortic V_{max} ≥4 m/s or mean ΔP ≥40 mm Hg • AVA typically is ≤1.0 cm^2 (or AVAi ≤0.6 cm^2/m^2) • Very severe AS is an aortic V_{max} ≥5 m/s or mean ΔP ≥60 mm Hg	• LV diastolic dysfunction • Mild LV hypertrophy • Normal LVEF	• None: Exercise testing is reasonable to confirm symptom status
C2	Asymptomatic severe AS with LV dysfunction	• Severe leaflet calcification or congenital stenosis with severely reduced leaflet opening	• Aortic V_{max} ≥4 m/s or mean ΔP ≥40 mm Hg • AVA typically ≤1.0 cm^2 (or AVAi ≤0.6 cm^2/m^2)	• LVEF <50%	• None
D: Symptomatic severe AS					
D1	Symptomatic severe high-gradient AS	• Severe leaflet calcification or congenital stenosis with severely reduced leaflet opening	• Aortic V_{max} ≥4 m/s or mean ΔP ≥40 mm Hg • AVA typically ≤1.0 cm^2 (or AVAi ≤0.6 cm^2/m^2) but may be larger with mixed AS/AR	• LV diastolic dysfunction • LV hypertrophy • Pulmonary hypertension may be present	• Exertional dyspnea or decreased exercise tolerance • Exertional angina • Exertional syncope or presyncope
D2	Symptomatic severe low-flow/low-gradient AS with reduced LVEF	• Severe leaflet calcification with severely reduced leaflet motion	• AVA ≤1.0 cm^2 with resting aortic V_{max} <4 m/s or mean ΔP <40 mm Hg • Dobutamine stress echocardiography shows AVA ≤1.0 cm^2 with V_{max} ≥4 m/s at any flow rate	• LV diastolic dysfunction • LV hypertrophy • LVEF <50%	• HF • Angina • Syncope or presyncope
D3	Symptomatic severe low-gradient AS with normal LVEF or paradoxical low-flow severe AS	• Severe leaflet calcification with severely reduced leaflet motion	• AVA ≤1.0 cm^2 with aortic V_{max} <4 m/s or mean ΔP <40 mm Hg • Indexed AVA ≤0.6 cm^2/m^2 and • Stroke volume index <35 mL/m^2 • Measured when patient is normotensive (systolic BP <140 mm Hg)	• Increased LV relative wall thickness • Small LV chamber with low stroke volume • Restrictive diastolic filling • LVEF ≥50%	• HF • Angina • Syncope or presyncope

AR indicates aortic regurgitation; AS, aortic stenosis; AVA, aortic valve area; AVAi, aortic valve area indexed to body surface area; BP, blood pressure; HF, heart failure; LV, left ventricular; LVEF, left ventricular ejection fraction; ΔP, pressure gradient; and V_{max}, maximum aortic velocity.

Table 9. Stages of Chronic AR

Stage	Definition	Valve Anatomy	Valve Hemodynamics	Hemodynamic Consequences	Symptoms
A	At risk of AR	• Bicuspid aortic valve (or other congenital valve anomaly) • Aortic valve sclerosis • Diseases of the aortic sinuses or ascending aorta • History of rheumatic fever or known rheumatic heart disease • IE	• AR severity: none or trace	• None	• None
B	Progressive AR	• Mild-to-moderate calcification of a trileaflet valve bicuspid aortic valve (or other congenital valve anomaly) • Dilated aortic sinuses • Rheumatic valve changes • Previous IE	• **Mild AR:** ○ Jet width <25% of LVOT; ○ Vena contracta <0.3 cm; ○ RVol <30 mL/beat; ○ RF <30%; ○ ERO <0.10 cm^2; ○ Angiography grade 1+ • **Moderate AR:** ○ Jet width 25%–64% of LVOT; ○ Vena contracta 0.3–0.6 cm; ○ RVol 30–59 mL/beat; ○ RF 30%–49%; ○ ERO 0.10–0.29 cm^2; ○ Angiography grade 2+	• Normal LV systolic function • Normal LV volume or mild LV dilation	• None
C	Asymptomatic severe AR	• Calcific aortic valve disease • Bicuspid valve (or other congenital abnormality) • Dilated aortic sinuses or ascending aorta • Rheumatic valve changes • IE with abnormal leaflet closure or perforation	• **Severe AR:** ○ Jet width ≥65% of LVOT; ○ Vena contracta >0.6 cm; ○ Holodiastolic flow reversal in the proximal abdominal aorta ○ RVol ≥60 mL/beat; ○ RF ≥50%; ○ ERO ≥0.3 cm^2; ○ Angiography grade 3+ to 4+; ○ In addition, diagnosis of chronic severe AR requires evidence of LV dilation	**C1:** Normal LVEF (≥50%) and mild-to-moderate LV dilation (LVESD ≤50 mm) **C2:** Abnormal LV systolic function with depressed LVEF (<50%) or severe LV dilatation (LVESD >50 mm or indexed LVESD >25 mm/m^2)	• None; exercise testing is reasonable to confirm symptom status
D	Symptomatic severe AR	• Calcific valve disease • Bicuspid valve (or other congenital abnormality) • Dilated aortic sinuses or ascending aorta • Rheumatic valve changes • Previous IE with abnormal leaflet closure or perforation	• **Severe AR:** ○ Doppler jet width ≥65% of LVOT; ○ Vena contracta >0.6 cm; ○ Holodiastolic flow reversal in the proximal abdominal aorta; ○ RVol ≥60 mL/beat; ○ RF ≥50%; ○ ERO ≥0.3 cm^2; ○ Angiography grade 3+ to 4+; ○ In addition, diagnosis of chronic severe AR requires evidence of LV dilation	• Symptomatic severe AR may occur with normal systolic function (LVEF ≥50%), mild-to-moderate LV dysfunction (LVEF 40%–50%), or severe LV dysfunction (LVEF <40%); • Moderate-to-severe LV dilation is present	• Exertional dyspnea or angina or more severe HF symptoms

AR indicates aortic regurgitation; ERO, effective regurgitant orifice; HF, heart failure; IE, infective endocarditis; LV, left ventricular; LVEF, left ventricular ejection fraction; LVESD, left ventricular end-systolic dimension; LVOT, left ventricular outflow tract; RF, regurgitant fraction; and RVol, regurgitant volume.

Table 15. Stages of *Primary* MR

Grade	Definition	Valve Anatomy	Valve Hemodynamics*	Hemodynamic Consequences	Symptoms
A	At risk of MR	• Mild mitral valve prolapse with normal coaptation • Mild valve thickening and leaflet restriction	• No MR jet or small central jet area <20% LA on Doppler • Small vena contracta <0.3 cm	• None	• None
B	Progressive MR	• Severe mitral valve prolapse with normal coaptation • Rheumatic valve changes with leaflet restriction and loss of central coaptation • Prior IE	• Central jet MR 20%–40% LA or late systolic eccentric jet MR • Vena contracta <0.7 cm • Regurgitant volume <60 mL • Regurgitant fraction <50% • ERO <0.40 cm^2 • Angiographic grade 1–2+	• Mild LA enlargement • No LV enlargement • Normal pulmonary pressure	• None
C	Asymptomatic severe MR	• Severe mitral valve prolapse with loss of coaptation or flail leaflet • Rheumatic valve changes with leaflet restriction and loss of central coaptation • Prior IE • Thickening of leaflets with radiation heart disease	• Central jet MR >40% LA or holosystolic eccentric jet MR • Vena contracta ≥0.7 cm • Regurgitant volume ≥60 mL • Regurgitant fraction ≥50% • ERO ≥0.40 cm^2 • Angiographic grade 3–4+	• Moderate or severe LA enlargement • LV enlargement • Pulmonary hypertension may be present at rest or with exercise • **C1:** LVEF >60% and LVESD <40 mm • **C2:** LVEF ≤60% and LVESD ≥40 mm	• None
D	Symptomatic severe MR	• Severe mitral valve prolapse with loss of coaptation or flail leaflet • Rheumatic valve changes with leaflet restriction and loss of central coaptation • Prior IE • Thickening of leaflets with radiation heart disease	• Central jet MR >40% LA or holosystolic eccentric jet MR • Vena contracta ≥0.7 cm • Regurgitant volume ≥60 mL • Regurgitant fraction ≥50% • ERO ≥0.40 cm^2 • Angiographic grade 3–4+	• Moderate or severe LA enlargement • LV enlargement • Pulmonary hypertension present	• Decreased exercise tolerance • Exertional dyspnea

*Several valve hemodynamic criteria are provided for assessment of MR severity, but not all criteria for each category will be present in each patient. Categorization of MR severity as mild, moderate, or severe depends on data quality and integration of these parameters in conjunction with other clinical evidence.

Table 2. Stages of Secondary MR (Table 16 in the 2014 VHD Guideline)

Grade	Definition	Valve Anatomy	Valve Hemodynamics*	Associated Cardiac Findings	Symptoms
A	At risk of MR	• Normal valve leaflets, chords, and annulus in a patient with coronary disease or cardiomyopathy	• No MR jet or small central jet area <20% LA on Doppler • Small vena contracta <0.30 cm	• Normal or mildly dilated LV size with fixed (infarction) or inducible (ischemia) regional wall motion abnormalities • Primary myocardial disease with LV dilation and systolic dysfunction	• Symptoms due to coronary ischemia or HF may be present that respond to revascularization and appropriate medical therapy
B	Progressive MR	• Regional wall motion abnormalities with mild tethering of mitral leaflet • Annular dilation with mild loss of central coaptation of the mitral leaflets	• ERO <0.40 cm^2† • Regurgitant volume <60 mL • Regurgitant fraction <50%	• Regional wall motion abnormalities with reduced LV systolic function • LV dilation and systolic dysfunction due to primary myocardial disease	• Symptoms due to coronary ischemia or HF may be present that respond to revascularization and appropriate medical therapy
C	Asymptomatic severe MR	• Regional wall motion abnormalities and/or LV dilation with severe tethering of mitral leaflet • Annular dilation with severe loss of central coaptation of the mitral leaflets	• ERO ≥0.40 cm^2 † • Regurgitant volume ≥60 mL • Regurgitant fraction ≥50%	• Regional wall motion abnormalities with reduced LV systolic function • LV dilation and systolic dysfunction due to primary myocardial disease	• Symptoms due to coronary ischemia or HF may be present that respond to revascularization and appropriate medical therapy
D	Symptomatic severe MR	• Regional wall motion abnormalities and/or LV dilation with severe tethering of mitral leaflet • Annular dilation with severe loss of central coaptation of the mitral leaflets	• ERO ≥0.40 cm^2† • Regurgitant volume ≥60 mL • Regurgitant fraction ≥50%	• Regional wall motion abnormalities with reduced LV systolic function • LV dilation and systolic dysfunction due to primary myocardial disease	• HF symptoms due to MR persist even after revascularization and optimization of medical therapy • Decreased exercise tolerance • Exertional dyspnea

*Several valve hemodynamic criteria are provided for assessment of MR severity, but not all criteria for each category will be present in each patient. Categorization of MR severity as mild, moderate, or severe depends on data quality and integration of these parameters in conjunction with other clinical evidence.
†The measurement of the proximal isovelocity surface area by 2D TTE in patients with secondary MR underestimates the true ERO because of the crescentic shape of the proximal convergence.

Table 11. Stages of MS

Stage	Definition	Valve Anatomy	Valve Hemodynamics	Hemodynamic Consequences	Symptoms
A	At risk of MS	• Mild valve doming during diastole	• Normal transmitral flow velocity	None	• None
B	Progressive MS	• Rheumatic valve changes with commissural fusion and diastolic doming of the mitral valve leaflets • Planimetered MVA >1.5 cm^2	• Increased transmitral flow velocities • MVA >1.5 cm^2 • Diastolic pressure half-time <150 ms	• Mild-to-moderate LA enlargement • Normal pulmonary pressure at rest	• None
C	Asymptomatic severe MS	• Rheumatic valve changes with commissural fusion and diastolic doming of the mitral valve leaflets • Planimetered MVA ≤1.5 cm^2 • (MVA ≤1.0 cm^2 with very severe MS)	• MVA ≤1.5 cm^2 • (MVA ≤1.0 cm^2 with very severe MS) • Diastolic pressure half-time ≥150 ms • (Diastolic pressure half-time ≥220 ms with very severe MS)	• Severe LA enlargement • Elevated PASP >30 mm Hg	• None
D	Symptomatic severe MS	• Rheumatic valve changes with commissural fusion and diastolic doming of the mitral valve leaflets • Planimetered MVA ≤1.5 cm^2	• MVA ≤1.5 cm^2 • (MVA ≤1.0 cm^2 with very severe MS) • Diastolic pressure half-time ≥150 ms • (Diastolic pressure half-time ≥220 ms with very severe MS)	• Severe LA enlargement • Elevated PASP >30 mm Hg	• Decreased exercise tolerance • Exertional dyspnea

The transmitral mean pressure gradient should be obtained to further determine the hemodynamic effect of the MS and is usually >5 mm Hg to 10 mm Hg in severe MS; however, due to the variability of the mean pressure gradient with heart rate and forward flow, it has not been included in the criteria for severity.

LA indicates left atrial; LV, left ventricular; MS, mitral stenosis; MVA, mitral valve area; and PASP, pulmonary artery systolic pressure.

Table 17. Stages of TR

Stage	Definition	Valve Anatomy	Valve Hemodynamics*	Hemodynamic Consequences	Symptoms
A	At risk of TR	**Primary** • Mild rheumatic change • Mild prolapse • Other (e.g., IE with vegetation, early carcinoid deposition, radiation) • Intra-annular RV pacemaker or ICD lead • Postcardiac transplant (biopsy related) **Functional** • Normal • Early annular dilation	• No or trace TR	• None	• None or in relation to other left heart or pulmonary/pulmonary vascular disease
B	Progressive TR	**Primary** • Progressive leaflet deterioration/destruction • Moderate-to-severe prolapse, limited chordal rupture **Functional** • Early annular dilation • Moderate leaflet tethering	**Mild TR** • Central jet area <5.0 cm^2 • Vena contracta width not defined • CW jet density and contour: soft and parabolic • Hepatic vein flow: systolic dominance **Moderate TR** • Central jet area 5–10 cm^2 • Vena contracta width not defined but <0.70 cm • CW jet density and contour: dense, variable contour • Hepatic vein flow: systolic blunting	**Mild TR** • RV/RA/IVC size normal **Moderate TR** • No RV enlargement • No or mild RA enlargement • No or mild IVC enlargement with normal respirophasic variation • Normal RA pressure	• None or in relation to other left heart or pulmonary/pulmonary vascular disease
C	Asymptomatic severe TR	**Primary** • Flail or grossly distorted leaflets **Functional** • Severe annular dilation (>40 mm or 21 mm/m^2) • Marked leaflet tethering	• Central jet area >10.0 cm^2 • Vena contracta width >0.7 cm • CW jet density and contour: dense, triangular with early peak • Hepatic vein flow: systolic reversal	• RV/RA/IVC dilated with decreased IVC respirophasic variation • Elevated RA pressure with "c-V" wave • Diastolic interventricular septal flattening may be present	• None, or in relation to other left heart or pulmonary/pulmonary vascular disease
D	Symptomatic severe TR	**Primary** • Flail or grossly distorted leaflets **Functional** • Severe annular dilation (>40 mm or >21 mm/m^2) • Marked leaflet tethering	• Central jet area >10.0 cm^2 • Vena contracta width >0.70 cm • CW jet density and contour: dense, triangular with early peak • Hepatic vein flow: systolic reversal	• RV/RA/IVC dilated with decreased IVC respirophasic variation • Elevated RA pressure with "c-V" wave • Diastolic interventricular septal flattening • Reduced RV systolic function in late phase	• Fatigue, palpitations, dyspnea, abdominal bloating, anorexia, edema

*Several valve hemodynamic criteria are provided for assessment of severity of TR, but not all criteria for each category will necessarily be present in every patient. Categorization of severity of TR as mild, moderate, or severe also depends on image quality and integration of these parameters with clinical findings.

CW indicates continuous wave; ICD, implantable cardioverter-defibrillator; IE, infective endocarditis; IVC, inferior vena cava; RA, right atrium; RV, right ventricle; and TR, tricuspid regurgitation.

Table 18. Stages of Severe TS

Stage	Definition	Valve Anatomy	Valve Hemodynamics	Hemodynamic Consequences	Symptoms
C, D	Severe TS	• Thickened, distorted, calcified leaflets	• T $^1/_2$ ≥190 ms • Valve area ≤1.0 cm^2	• RA/IVC enlargement	• None or variable and dependent on severity of associated valve disease and degree of obstruction

The transtricuspid diastolic gradient is highly variable and is affected by heart rate, forward flow, and phases of the respiratory cycle. However, severe TS usually has mean pressure gradients >5 to 10 mm Hg at heart rate 70 beats per minute.

bpm indicates beats per minute; IVC, inferior vena cava; RA, right atrium; T $^1/_2$, pressure half-time; and TS, tricuspid stenosis (9).

Table 19. Stages of Severe Pulmonic Regurgitation

Stage	Definition	Valve Anatomy	Valve Hemodynamics	Hemodynamic Consequences	Symptoms
C, D	Severe PR	• Distorted or absent leaflets, annular dilation	• Color jet fills RVOT • CW jet density and contour: dense laminar flow with steep deceleration slope; may terminate abruptly	• Paradoxical septal motion (volume overload pattern) • RV enlargement	• None or variable and dependent on cause of PR and RV function

CW indicates continuous wave; PR, pulmonic regurgitation; RV, right ventricular; and RVOT, right ventricular outflow tract (247).

Table 20. Stages of Severe Pulmonic Stenosis

Stage	Definition	Valve Anatomy	Valve Hemodynamics	Hemodynamic Consequences	Symptoms
C, D	Severe PS	• Thickened, distorted, possibly calcified leaflets with systolic doming and/or reduced excursion • Other anatomic abnormalities may be present, such as narrowed RVOT	• V_{max} >4 m/s; peak instantaneous gradient >64 mm Hg	• RVH • Possible RV, RA enlargement • Poststenotic enlargement of main PA	• None or variable and dependent on severity of obstruction

PA indicates pulmonary artery; PS, pulmonic stenosis; RA, right atrium; RV, right ventricle; RVH, right ventricular hypertrophy; RVOT, right ventricular outflow; and V_{max}, maximal pulmonic valve jet velocity (9).

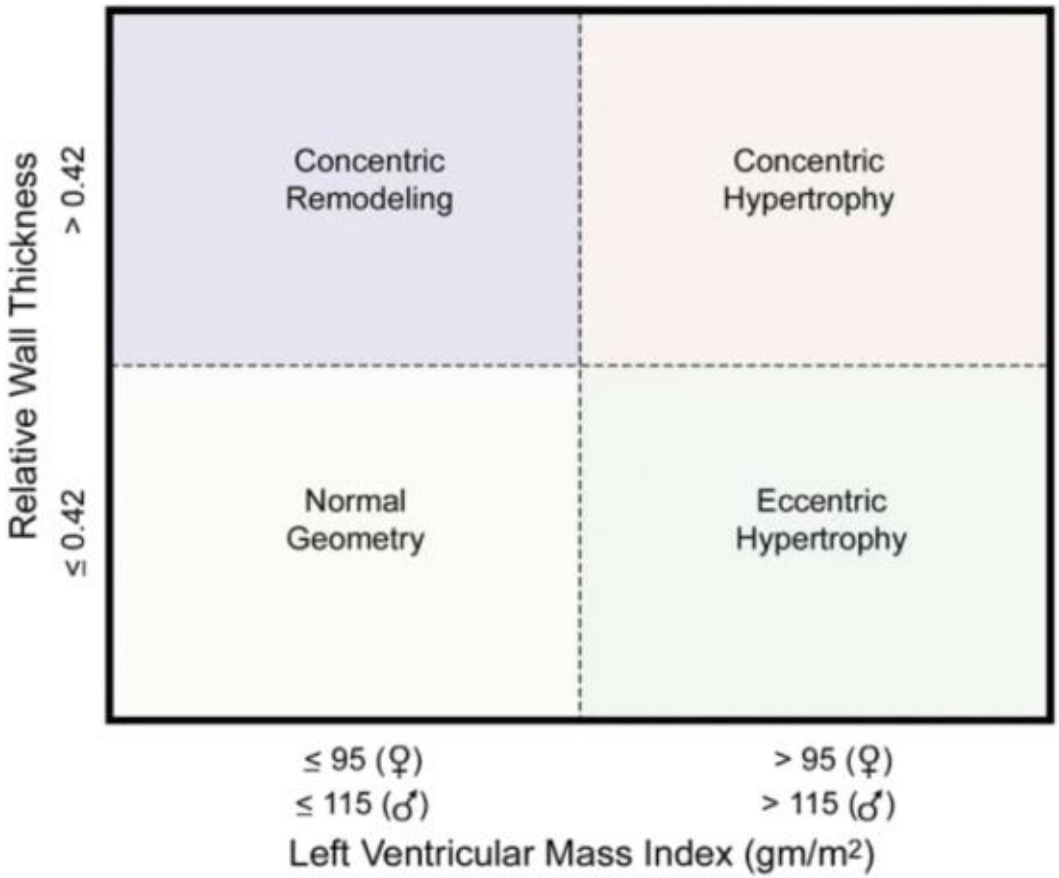
Relative Wall Thickness
> 0.42
≤ 0.42
Concentric Remodeling
Concentric Hypertrophy
Normal Geometry
Eccentric Hypertrophy
≤ 95 (♀)
≤ 115 (♂)
> 95 (♀)
> 115 (♂)
Left Ventricular Mass Index (gm/m2)

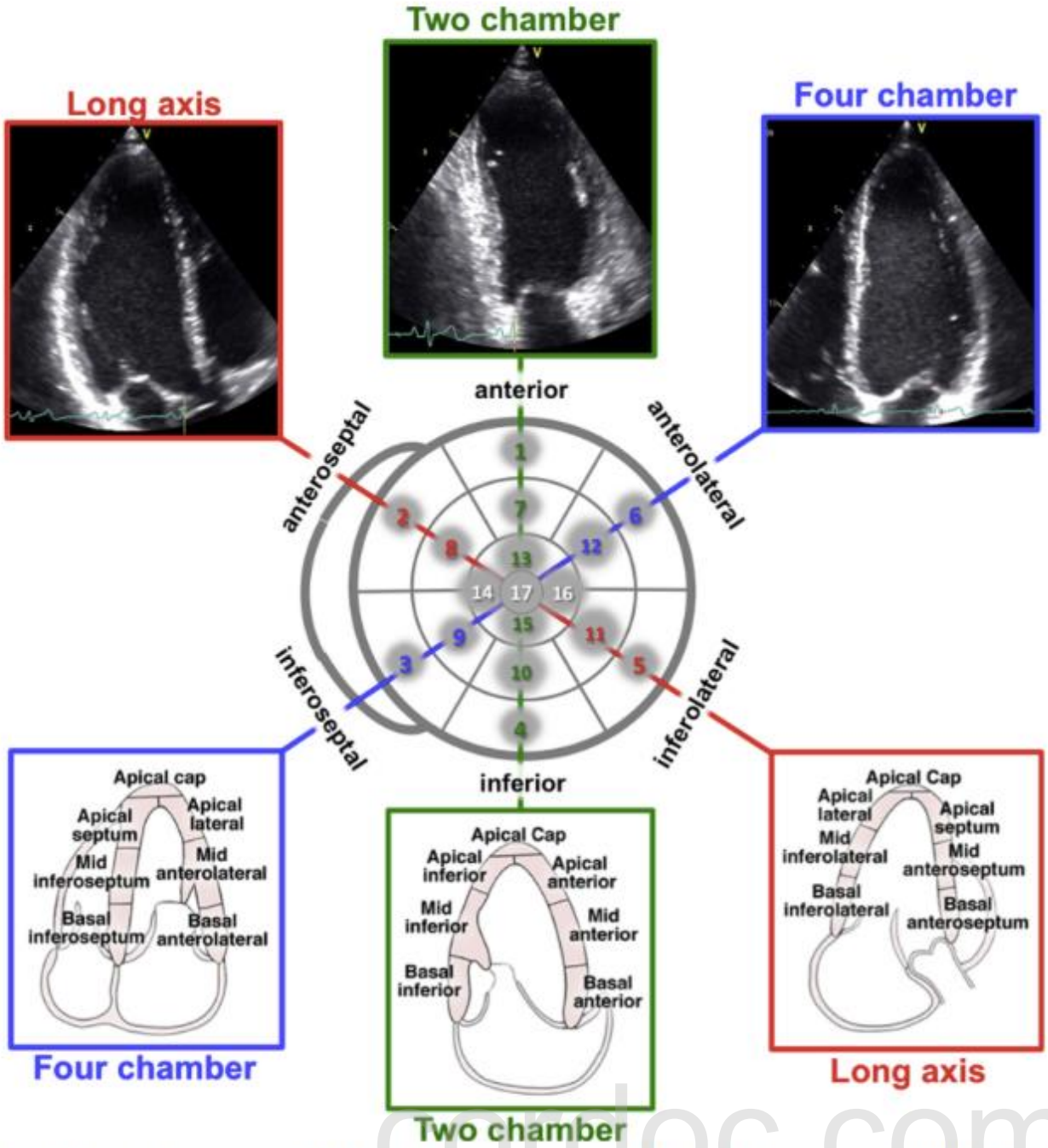
Two chamber
Long axis
Four chamber
anterior
anteroseptal
anterolateral
inferoseptal
inferolateral
inferior
1
2
3
4
5
6
7
8
9
10
11
12
13
14
15
16
17
Apical cap
Apical septum
Apical lateral
Mid inferoseptum
Mid anterolateral
Basal inferoseptum
Basal anterolateral
Four chamber
Apical Cap
Apical inferior
Apical anterior
Mid inferior
Mid anterior
Basal inferior
Basal anterior
Two chamber
Apical Cap
Apical lateral
Apical septum
Mid inferolateral
Mid anteroseptum
Basal inferolateral
Basal anteroseptum
Long axis